

Post Necrotizing Enterocolitis Colonic Strictures: Report of 5 Cases

Vinit K Thakur, Vijayendra Kumar, Ramdhani Yadav, Zaheer Hasan, Digamber Chaubey, Pankaj Kumar, Sandip Kumar Rahul*

Department of Pediatric Surgery, Indira Gandhi Institute of Medical Sciences, Patna, India

ABSTRACT

Background: With increasing survival of patients suffering from necrotizing enterocolitis (NEC) colonic strictures, as its late sequelae, is increasingly being seen and most of these patients present with chronic constipation.

Case Series: Five patients of acquired colonic stricture presenting with abdominal distension and constipation are being reported here. All five patients varied in clinical features, age at presentation and surgical management. Three of them had abdominal distension and constipation with poor nutritional status. Primary resection with anastomosis could be done in only one while stoma was made initially in other patients. One patient presented with sealed perforation and fistula between jejunum and colon. All, except one patient, had stricture at splenic flexure. Histopathology of colon reported normal ganglion cells in all patients.

Conclusion: All survivors of necrotizing enterocolitis, should be followed for the development of colonic stricture; It should be kept as important differential diagnoses of chronic constipation in children.

Key words: Colonic stricture; Constipation; Necrotizing enterocolitis

Correspondence*: Sandip Kumar Rahul, MS, M.Ch. Department of Paediatric Surgery, Indira Gandhi Institute of Medical Sciences, Patna, India.

E-mail: sandeep.rahul65@gmail.com © 2018, Thakur et al.

Submitted: 26.06.2018 Accepted: 18-09-2018

Conflict of Interest: None Source of Support: Nil

This is an open-access article distributed under the terms of the Creative Commons Attribution License, which permits unrestricted use, distribution, and reproduction in any medium, provided the original work is properly cited.

INTRODUCTION

With rising incidence of neonatal necrotizing enterocolitis (NEC) and increased number of these patients surviving due to advancement in intensive care, acquired colonic stricture and stenosis is no longer a rare entity in infants and children.[1-3] Presenting symptoms of difficulty in passage of stools and abdominal distension often resemble with other causes of chronic constipation which need to be differentiated for proper management.

We present our recent experience with five cases of patients with acquired colonic stricture.

CASE REPORT

Five patients with colonic strictures secondary to NEC are being reported here. The age at presentation and birth-weight are mentioned in table 1.

All patients presented with abdominal distension of variable duration associated with constipation, failure to thrive, and occasional episodes of vomiting. Patient number 4 had poor health status in addition to high-grade fever (102°F) at presentation. Patient 5 presented with acute abdomen. Patient 1, 3, and 5 had history of NICU admission in neonatal life for suspicion of NEC.

Clinical examination revealed abdominal distension in all. Abdominal tenderness was present in patient number 5. Laboratory investigations showed anemia and hypoproteinemia in all children with normal thyroid profile. In patient 4 dilated bowel loops were noted on X-ray abdomen and pneumoperitoneum in patient 5. Contrast enema was done in four patients which showed level of stricture.

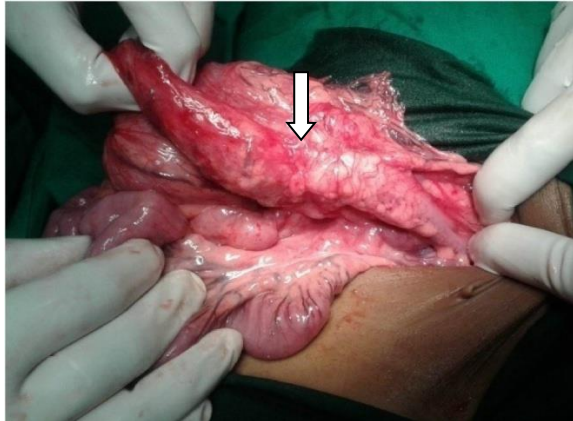


Figure 1: Stricture at splenic flexure of colon (Arrow-marked)

After optimization, all patients underwent exploratory laparotomy. Four patients had colonic strictures at splenic flexure of the colon (Figure 1) and in one patient at descending colon. Patient 4 also had jejuno-colic fistula at the level of stricture (Figure 2) which was sep-

arated along with repair of jejunum and colostomy was fashioned after resection of stenosed part of colon. Patient 5 had colonic perforation proximal to the stricture. Operative findings, surgical procedure, and outcomes are given in Table 1.

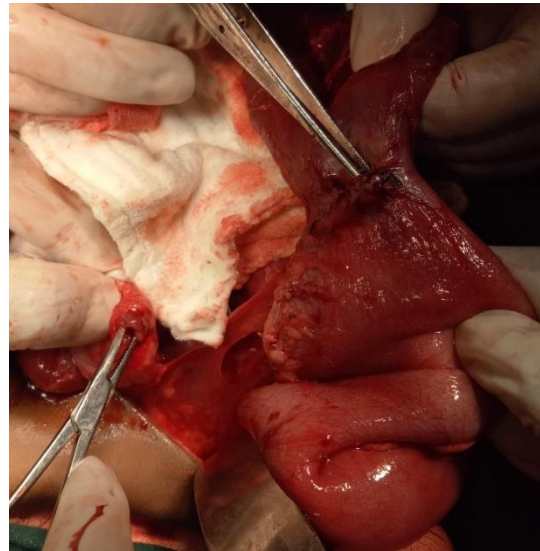


Figure 2: Fistulous communication between jejunum and colon

All patients had normal ganglion cells on histopathology of colon whereas histopathology of the stenosed portions showed non-specific inflammation and fibrosis. All five patients are on regular follow-up and doing well.

Table 1: Findings at the time of Examination, Investigation, Surgery and Post-operative period

| | Patient 1 | Patient2 | Patient3 | Patient4 | Patient 5 |
|-----------------------|--|---|---|---|---|
| Age at Presentation | 3 years | 1.5 months | 4 months | 1.2 years | 2 years |
| Birth weight | 1.8kg | 2kg | 1.8kg | 1.8kg | 2kg |
| Operative Findings | Stricture at the level of splenic flexure | Stricture at splenic flexure | Stricture at splenic flexure | Adhesions between bowel loops; Stricture in descending colon; fistulous communication between jejunum and descending colon | Perforation in transverse colon; stricture at the splenic flexure |
| Surgical Procedure | Resection of stenosed segment and end to end anastomosis | Initial resection and stoma formation; stoma closure after 4 months | Initial resection and stoma formation; stoma closure after 6 months | Division of fistula; jejunostomy and colostomy at the site of communication in colon; after 5 months of previous surgery, stoma closure is awaited. | Resection of the stenosed part with perforated segment; double barrel colostomy; colostomy closure after 6 months |
| Post-operative Period | Uneventful | Uneventful | Uneventful | Sepsis in post-operative period (managed conservatively) | Wound infection (managed conservatively) |

DISCUSSION

Acquired colonic stenosis (commonly referred to as stricture) develops in 10% to 25% of infants who suffered from NEC at birth.[1,2,4] Intestinal strictures develop irrespective of the mode of management of an acute episode of NEC. Eighty percent of these strictures are in colon, showing preference for left colon (splenic flexure, descending and sigmoid colon) as evident in our series too. [2] These strictures secondary to NEC, are usually reported to develop within 3 months of initial insult, however the presentation may be delayed till later childhood. [4] Our youngest patient presented at the age of 45 days and the oldest at 3 years. Phad et al reported strictures in 29.5% out of total 61 patients of NEC.[2]

Colonic strictures usually present with long standing history of constipation, abdominal distension, anorexia, nausea, vomiting, and weight loss.[1,2] Four of our patients had similar presentation whereas in one patient, the presentation was with acute abdomen due to colonic perforation proximal to colonic stricture. Mechanical obstruction due to colonic stricture might lead to proximal perforation.

History of NEC in the past, prematurity, low birth weight, being top-fed and ICU stay with abdominal distension are important points in history which may lead to a strong suspicion of post-NEC strictures. However, often proper history is not available and it is very difficult to reach to a conclusive diagnosis preoperatively. All of our patients were of low birth-weight and three patients had definitive history of NICU admission for NEC.

The other differential diagnoses may be Hirschsprung's disease (HD), chronic constipation, and rarely segmental dilatation of colon, delayed presenting perforated colonic web, and congenital colonic stenosis. [5-9] Contrast enema is good diagnostic modality to differentiate various conditions. In our series, 4 out of five patients had contrast enema showing disparity between proximal and distal colon and an intervening stenosed portion without a transitional zone thus differentiating it from HD.

It is known that, the visualization of recto-sigmoid transition zone is highly predictable of HD, but non-visualization does not rule out this condition. Although contrast enema and operative findings were highly suggestive of post NEC colonic stricture, we still ruled out HD on histopathology.

Histopathology is also helpful in differentiating congenital colonic stenosis and post NEC colonic strictures. In

our series, histopathology revealed non-specific inflammatory changes and fibrosis which is indicative of post inflammatory stricture formation. Few researchers have reported cytomegalovirus (CMV)-induced strictures in the colon. [6]

Treatment includes surgical resection and anastomosis to restore the continuity of the colon. Occasionally, primary continuity is deferred in case of suboptimal health status of the patient or development of complications.[10] In one patient we performed resection of the stenosed segment and primary colonic anastomosis, whereas in four patients an enterostomy was fashioned initially which was closed after 4-6 months except in one patient.

Separation of jejunocolic fistula and closure of the jejunum was also done in one case. In case of strong suspicion of HD, fresh frozen biopsies may be taken to rule out HD

Consent: Authors declared that they have taken informed written consent, for publication of this report along with clinical photographs/material, from the legal guardian of the patient with an understanding that every effort will be made to conceal the identity of the patient however it cannot be guaranteed.

Authors' Contribution: All authors contributed equally in concept, literature review, and drafting of the manuscript. Both authors approved the final version of this manuscript.

REFERENCES

1. Oldham KT, Arca MJ. From Atresia, Stricture, and other Obstructions of the colon. In: Pediatric Surgery. Volume 2. 6th edition. Edited by Grosfeld JL, O'Neill JA, Jr. Finkelsrud EW, Coran AG. Philadelphia: Elsevier; 2006;1494-5.
2. Phad N, Trivedi A, Todd D, Lakkundi A. Intestinal strictures post-necrotising enterocolitis: clinical profile and risk factors. *J Neonat Surg.* 2014; 3: 44.
3. Zhang H, Chen J, Wang Y, Deng C, Li L, Guo C. Predictive factors and clinical practice profile for strictures post-necrotising enterocolitis. *Medicine.* 2017;96:e6273.
4. Jainik JS, Ein SH, Mancor K. Intestinal stricture after necrotizing enterocolitis. *J Pediatr Surg.* 1981; 16:438-43.
5. Baker SS, Liptak GS, Colletti RB, Croffie JM, Di Lorenzo C, Ector W, et al. Constipation in infants and children: evaluation and treatment. A medical position statement of the North American Society for Pediatric Gastroenterology and Nutrition. *J Pediatr Gastroenterol Nutr.* 1999;29:612-26.
6. Kumar C, Luthra M. Cytomegalovirus as a cause of colonic stricture-simulating Hirschsprung's disease. *J Indian Assoc Pediatr Surg.* 2018;23:103-5.

7. Mirza B, Iqbal S, Ijaz L. Colonic atresia and stenosis:our experience.J Neonat Surg. 2012; 1: 4.
8. Pan P. Delayed presentation of colonic atresia masquerading constipation. Southeast Asian J Case Rep Rev. 2017; 6:2664-5.
9. Ragavan M, Arunkumar S, Balaji NS. Segmental dilatation of near total colon managed by colon preserving surgery. APSP J Case Rep. 2012; 3:18.
10. Gobet R, Sacher P, Schwobel MG. Surgical procedures in colonic strictures after necrotizing enterocolitis. Acta Paediatrica.1994; 396:77-9..